OSCRSJ · JUN 2026 · VOLUME 1 · ISSUE 1

PEER REVIEWED · QUARTERLY

OSCRSJ

Orthopedic Surgery Case Reports & Series Journal

OPEN ACCESS

Pan-echinocandin-resistant Candida glabrata periprosthetic hip joint infection in an immunosuppressed rheumatoid host: a case report

CASE REPORT

Param Tarong, MD[*,1], Renaldi Adityo Purwana, MD[1], Siti Mardro Semita, MD[1], Azir Andri Fatmawati, MD[2], Heni Gandi Dibyosubroto, MD[2], and Parama Nyoman Raharjo, MD[2]

[1] *Department of Orthopaedics and Traumatology, Faculty of Medicine, Universitas Diponegoro / Dr. Kariadi General Hospital, Semarang, Indonesia*

[2] *Department of Orthopaedics and Traumatology, Faculty of Medicine, Universitas Gadjah Mada / Dr. Sardjito General Hospital, Yogyakarta, Indonesia*

[*] Corresponding author

Introduction: Fungal periprosthetic joint infection (PJI) complicates 1–4% of all PJI and disproportionately affects immunosuppressed hosts. Non-albicans Candida species, particularly Candida glabrata, increasingly exhibit echinocandin resistance through FKS1 and FKS2 hot-spot mutations, but the orthopedic literature on resistant non-albicans Candida hip PJI remains small, and the 2019 International Consensus Meeting (ICM) does not stratify guidance by resistance phenotype.

Case Presentation: A woman in her late sixties with seropositive rheumatoid arthritis on prednisone and methotrexate presented 22 months after primary right cementless total hip arthroplasty (THA) with a six-month history of progressive right groin pain and a draining lateral sinus. An earlier outside-facility aspiration and debridement had been uninformative. Three of five intraoperative tissue samples and sonicate fluid grew Candida glabrata on Sabouraud dextrose agar; FKS2 sequencing identified a p.Phe659del mutation conferring pan-echinocandin resistance. Two-stage revision used a conventional-dose amphotericin-B-loaded cement spacer (200 mg per 40 g) with intravenous liposomal amphotericin B and oral flucytosine, later transitioned to oral posaconazole. A secondary extended-spectrum β-lactamase–producing Escherichia coli wound infection required repeat debridement. Stage II reimplantation with a cementless revision stem, a multi-hole uncemented acetabular shell, and a dual-mobility bearing was performed at five months, achieving Harris Hip Score 78 at one year. Reactivation at 20 months mandated salvage Girdlestone resection

[*]**Corresponding author:** Param Tarong, MD, Department of Orthopaedics and Traumatology, Faculty of Medicine, Universitas Diponegoro / Dr. Kariadi General Hospital, Semarang, Indonesia. Email: paramtarong@outlook.com.

Received: 2026-05-24 · **Accepted:** 2026-06-16 · **Published:** 2026-06-22

Disclosure: The authors declare no conflicts of interest. See Declarations.

© 2026 The Author(s). Published by OSCRSJ.

This article is distributed under the terms of the *Creative Commons Attribution 4.0 International License* (CC BY 4.0), which permits unrestricted use, distribution, and reproduction in any medium, provided the original work is properly cited. To view a copy of this license, visit https://creativecommons.org/licenses/by/4.0/

arthroplasty, underscoring that even a technically sound two-stage revision may not eradicate resistant non-albicans Candida PJI.

Discussion: This case highlights three lessons: the diagnostic findings that should prompt extended-incubation fungal culture and molecular susceptibility testing; the elution-driven limitations of conventional amphotericin-B-loaded cement spacers, which favour a liposomal formulation; and the realistic medium-term prognosis, with two-stage recurrence rates near 48% in contemporary non-albicans Candida PJI series.

Conclusion: Glabrata-complex PJI isolates should undergo echinocandin minimum inhibitory concentration testing and FKS1/FKS2 sequencing at speciation. Patients should be counselled pre-operatively about a meaningful probability of eventual joint salvage.

Keywords: *Candida glabrata*, *Prosthesis-Related Infections;*, *Arthroplasty*, *Rheumatoid Arthritis*

Introduction

Periprosthetic joint infection (PJI) complicates 1–2% of primary total hip arthroplasties (THA) and is the leading cause of early revision.[1] Fungal organisms account for 1–4% of all PJI — a share of infected joints, not of all primary arthroplasties — and are recognised in immunosuppressed hosts, after prolonged broad-spectrum antibiotic exposure, and in joints with prior bacterial PJI.[2,3]

Although Candida albicans remains the most frequently isolated species, non-albicans organisms, with C. glabrata and C. parapsilosis increasingly represented, now account for a rising share of contemporary fungal hip PJI.[3,4] C. glabrata carries intrinsic reduced susceptibility to fluconazole and has demonstrated rising acquired resistance to echinocandins through hot-spot mutations in the FKS1 and FKS2 genes encoding β-1,3-D-glucan synthase.[5]

The 2019 International Consensus Meeting (ICM) Hip and Knee Section on Fungal PJI recommends two-stage exchange arthroplasty with antifungal-impregnated cement spacers and recommends against debridement, antibiotics and implant retention (DAIR); the consensus notes the absence of high-quality evidence to guide antifungal selection in resistant non-albicans Candida.[6] Subsequent reviews echo these recommendations while highlighting outcome heterogeneity.[4,7]

We report a case of pan-echinocandin-resistant C. glabrata PJI of a primary cementless THA in an immunosuppressed rheumatoid host, with FKS2 hot-spot sequencing identifying a p.Phe659del mutation. We use the case to highlight three lessons: the diagnostic findings that should prompt extended-incubation fungal culture and molecular susceptibility testing; the elution-driven limitations of conventional amphotericin-B-loaded cement spacers, which favour a liposomal formulation; and the realistic medium-term prognosis, with two-stage recurrence rates near 48% in contemporary non-albicans Candida PJI series. This report adheres to the CARE (CAse REport) reporting guideline, and the clinical course is summarised as a timeline in Table 1.

Case presentation

A woman in her late sixties presented with a six-month history of progressive right groin pain, intermittent low-grade fevers, and a recently developed lateral sinus over the right hip. She had seropositive rheumatoid arthritis of 15 years' standing managed with prednisone (5–7.5 mg daily) and methotrexate (15 mg weekly). A primary right cementless THA had been performed at an outside facility 22 months earlier for inflammatory coxarthropathy. Four months before presentation she had completed broad-spectrum antibiotics for a urinary tract infection.

Three months after the primary THA she had developed transient right groin pain; hip aspiration at that time at an outside facility returned no growth on routine bacterial culture. Approximately six months later the pain returned, and an outside-facility debridement grew a coagulase-negative staphylococcus from one of three cultures, interpreted there as a likely skin contaminant. She was started empirically on oral cephalexin. Symptoms then waxed and waned before becoming progressively worse over the six months preceding referral; a draining sinus emerged over the lateral hip, and she was referred to our service. The clinical course is summarised in Table 1.

On examination the right hip was painful through arc with a Trendelenburg gait, a clean but draining sinus over the greater trochanter, and no neurovascular deficit. Plain radiographs of the right hip demonstrated the primary cementless total hip arthroplasty in situ, without radiographic evidence of component loosening (Figure 1). Inflammatory markers were modestly elevated (ESR 58 mm/hr; CRP 32 mg/L). Aspiration yielded turbid fluid with a synovial white-cell count of 4,200 cells/μL and 78% neutrophils; routine bacterial culture was negative. With reference to the 2018 ICM diagnostic criteria, the cell count was just above the minor criterion threshold of 3,000 cells/μL

and the polymorphonuclear percentage was just below the conventional 80% threshold; the actively draining sinus communicating with the joint nevertheless constituted a major criterion.[8] Because the draining sinus is itself a major criterion, the diagnosis did not rest on the synovial cell-count thresholds; the 2018 ICM values are reported here for completeness, and the higher chronic-hip threshold of Higuera and colleagues, discussed below, is cited only as a comparator optimised for chronic presentations.

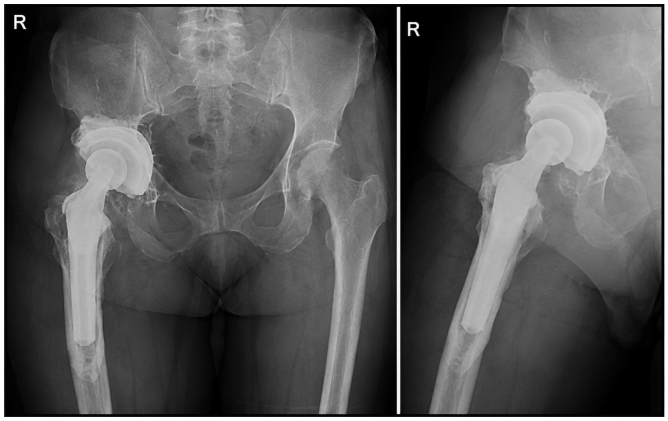

Figure 1. Anteroposterior and lateral radiographs of the right hip at presentation, demonstrating the primary cementless total hip arthroplasty in situ.

Stage I revision was performed under combined spinal-epidural anaesthesia. Intraoperative purulence was encountered around the femoral component, the implants were explanted, and an antibiotic- and antifungal-loaded PMMA articulating spacer (1 g vancomycin and 200 mg amphotericin B per 40-g batch of cement) was placed. Five separate intraoperative tissue samples were sent on bacterial and fungal media, in line with the 2019 ICM recommendation for ≥3 samples and extended-incubation fungal culture for up to 21 days, along with sonicate fluid and one specimen for fungal molecular workup.[6] Bacterial cultures returned no growth at day 7. Fungal cultures from three of five samples and from the sonicate fluid grew Candida glabrata on Sabouraud dextrose agar after 5–9 days (Figure 2). Minimum inhibitory concentrations (broth microdilution, CLSI M27) were caspofungin 2 µg/mL, micafungin 1 µg/mL, and anidulafungin 1 µg/mL, all above the CLSI resistance breakpoints of 0.5, 0.25, and 0.5 µg/mL respectively; fluconazole ≥256 µg/mL (resistant); posaconazole 0.5 µg/mL (within the wild-type epidemiological cut-off); and amphotericin B 0.5 µg/mL. FKS2 hot-spot sequencing identified a phenylalanine-659 deletion (p.Phe659del) consistent with pan-echinocandin resistance.[5]

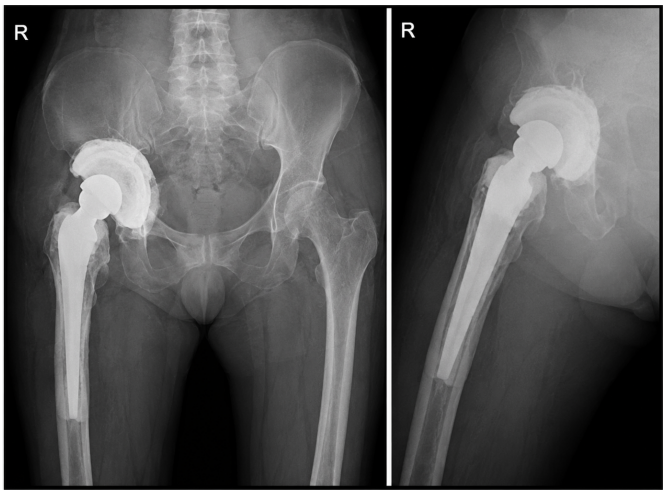

Figure 2. Photomicrograph of Candida glabrata colonies recovered on Sabouraud dextrose agar at day 9 of incubation from intraoperative tissue samples obtained at Stage I revision. Magnification ×40; lactophenol cotton blue stain.

After multidisciplinary discussion with infectious diseases, the patient was started on intravenous liposomal amphotericin B (5 mg/kg daily) combined with oral flucytosine (25 mg/kg every six hours), in line with the IDSA 2016 candidiasis guideline recommendation for combination salvage therapy in echinocandin-resistant C. glabrata deep-seated infection.[9] Renal function and serum flucytosine troughs were monitored twice weekly. In line with the 2017 ACR/AAHKS perioperative guideline, methotrexate was held and prednisone reduced to 5 mg daily.[10]

At postoperative week two, new wound drainage and lateral dehiscence prompted repeat debridement; cultures yielded an extended-spectrum β-lactamase–producing Escherichia coli sensitive to meropenem, and a second batch of amphotericin-B-loaded cement beads was placed. Intravenous meropenem was added; the wound healed slowly and sutures were removed at postoperative day 28. Systemic antifungal therapy was continued for 12 weeks total, with the final four weeks transitioned to oral posaconazole at therapeutic trough.

Stage II reimplantation was undertaken five months after explantation, following two successive serum CRP measurements within reference range and a negative aspiration culture. Bone loss was Paprosky IIIA on the femoral side and Paprosky IIB on the acetabular side. Reconstruction comprised a cementless extensively porous-coated modular revision femoral stem for diaphyseal fixation of the Paprosky IIIA femoral bone loss, and a multi-hole highly-porous uncemented acetabular shell with screw augmentation and morsellised allograft impaction at the acetabular floor for the Paprosky IIB acetabular defect. A dual-mobility bearing was selected to mitigate the elevated dislocation

risk imparted by two-stage revision and abductor compromise. Five intraoperative tissue samples from Stage II returned no growth at extended incubation.

Progressive weightbearing on a walking aid was achieved by week six, and the Harris Hip Score at one year was 78. Methotrexate was resumed at low dose by month four. The patient remained clinically and serologically quiescent through 20 months, at which point a new draining sinus appeared and repeat aspirate cultures grew C. glabrata of the same susceptibility pattern. After multidisciplinary review she elected, at an outside facility nearer her home, for salvage Girdlestone resection arthroplasty rather than further revision (Figure 3).

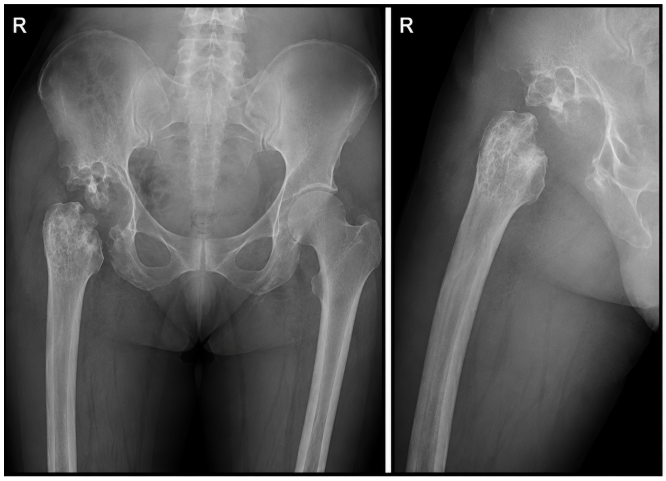

Figure 3. Anteroposterior radiograph of the right hip after salvage Girdlestone resection arthroplasty performed at 20 months following Stage II reimplantation.

Discussion

This case illustrates the complexity of pan-echinocandin-resistant C. glabrata hip PJI in an immunosuppressed rheumatoid host. The 2019 ICM consensus provides a general framework but does not stratify by resistance phenotype, and the orthopedic literature on FKS-mutated C. glabrata PJI remains small.[4,6]

Two prior aspirations and one outside-facility debridement preceded the correct diagnosis. Aspiration-negative chronic PJI in an immunosuppressed host is a recognised pitfall. Routine bacterial media incubated for 5–7 days are inadequate for Candida, which require Sabouraud dextrose agar and extended incubation of 14–21 days; the 2019 ICM consensus explicitly recommends this protocol.[6] Conventional and commercial yeast-identification platforms may misidentify a non-trivial proportion of yeast isolates, including those within species complexes, supporting the role of molecular confirmation in PJI workup.[11]

Higuera and colleagues identified an optimal chronic-hip threshold of 3,966 cells/μL with PMN ≥80%.[12] We cite this chronic-hip-specific threshold alongside the 2018 ICM minor criterion of 3,000 cells/μL because the two answer different questions: the ICM value defines the formal diagnostic minor criterion, whereas the Higuera threshold is optimised specifically for chronic hip PJI. The borderline result in our patient is characteristic of the blunting that inflammatory arthritis and immunosuppression impose. Rheumatoid arthritis itself carries an approximately 1.6-fold higher PJI risk than osteoarthritis at primary arthroplasty, with immunosuppressive regimens contributing additional susceptibility.[13]

The 2019 ICM consensus recommends two-stage exchange with an antifungal-impregnated spacer and recommends against DAIR for fungal PJI, given the dense, drug-resistant biofilms that Candida species form on prosthetic surfaces.[6] Contemporary systematic reviews, including the 489-joint review by Shang and colleagues, report that approximately 59% of cases are managed with two-stage exchange, with two-stage recurrence rates near 48%, substantially worse than success rates typically reported for bacterial PJI.[4,7]

The secondary ESBL E. coli wound infection at two weeks merits comment: bacterial coinfection has been shown to confer a substantially worse prognosis than monomicrobial fungal PJI and has been reported in cohort data as one of the strongest single negative prognostic signals.[14] We present this as a cohort-level association rather than something our single case can establish; in this patient it is consistent with, and may help to contextualise, the late reactivation.

Systemic therapy followed the IDSA 2016 guideline recommendation of liposomal amphotericin B plus flucytosine for echinocandin-resistant C. glabrata deep-seated infection.[9] Twelve weeks total therapy is at the upper end of published practice, consistent with the Azzam multi-institutional series recommendation that unusual or virulent organisms warrant a longer course.[15]

Local antifungal delivery is more controversial. We used 200 mg of conventional (deoxycholate) amphotericin B per 40 g cement. In vitro studies have shown that cumulative amphotericin B release from PMMA is below 0.03% of the loaded dose over the first week.[16] In practical terms, of the 200 mg loaded into each 40-g batch, well under 1 mg is released locally during the early interval when spacer-derived antifungal cover matters most. Houdek and colleagues subsequently demonstrated that higher-dose (7.5%) deoxycholate beads can elute at clinically useful concentrations (peak 0.33 μg/mL at 8 hours), but the cumulative fraction released remains small.[17] Liposomal

formulations of amphotericin B have shown substantially better elution from PMMA in subsequent benchtop work, and on the strength of this evidence we would now consider a higher-dose liposomal preparation, recognising that its benchtop elution advantage warrants further clinical evaluation before it can be regarded as established practice.

Bone loss at Stage II was Paprosky IIIA on the femoral side and Paprosky IIB on the acetabular side. Reconstruction was tailored to the bone loss pattern and to the elevated dislocation risk imparted by two-stage revision, abductor compromise, and Paprosky-II acetabular deficiency. The Harris Hip Score of 78 at one year is comparable to published medium-term outcomes in this bone-loss class.

Reactivation at 20 months and conversion to Girdlestone are consistent with published outcomes for non-albicans Candida PJI managed with two-stage exchange, where reported two-stage recurrence rates reach approximately 48% in the 489-joint systematic review by Shang and colleagues and salvage resection is required in a meaningful minority.[2,4] Three practical points emerge: glabrata-complex isolates should undergo MIC testing against all three echinocandins together with FKS1/FKS2 hot-spot sequencing at speciation rather than after empirical failure; antifungal-loaded spacers should preferentially use the liposomal formulation of amphotericin B given superior elution; and a longer-than-usual interstage interval together with two consecutive normal CRPs and a negative pre-reimplantation aspirate should precede Stage II.[15]

This study does not come without its limitations. The findings rest on one patient and one isolate, the data were collected retrospectively, and the final salvage procedure and its outcome were captured in part at an outside facility nearer the patient's home rather than under our direct observation. These limitations temper the generalisability of the prognostic and management inferences drawn above.

Conclusion

Echinocandin-resistant C. glabrata is an emerging cause of fungal hip PJI in immunosuppressed hosts and is frequently mis-speciated by routine laboratory platforms. In this case, guideline-concordant two-stage revision with conventional-dose antifungal-loaded cement, combination systemic antifungal therapy, optimisation of host immunosuppression, and bone-loss-adapted reconstruction failed to eradicate infection. Harris Hip Score 78 at one year sits in the 'fair' category, and the result fell to functional resection arthroplasty within two years of reimplantation. This trajectory is consistent with published recurrence rates near 48% in contemporary non-albicans Candida series and underscores that even technically sound two-stage revision cannot reliably eradicate resistant non-albicans Candida PJI in an immunosuppressed host. We recommend that all glabrata-complex PJI isolates undergo MIC testing against all three echinocandins and FKS1/FKS2 hot-spot sequencing at speciation, and that patients be counselled pre-operatively about the realistic probability of eventual joint salvage. Diagnostic criteria and management guidelines specific to resistance-stratified non-albicans Candida PJI remain an unmet need.

Declarations

Funding: No external funding was received for this work.

Conflicts of Interest: The authors declare no conflicts of interest. The full disclosure of potential conflicts of interest is provided with the online version of this article.

Patient Consent: Written informed consent was obtained from the patient for publication of this case report and any accompanying images.

IRB / Ethics Approval: Institutional Review Board approval was not required for this report per institutional policy.

Data Availability: Data available on reasonable request

Author Contributions (CRediT): P.T. — Writing — review & editing; Writing — original draft; R.A.P. — Writing — review & editing; S.M.S. — Writing — review & editing; A.A.F. — Writing — review & editing; Data curation; Validation; H.G.D. — Writing — review & editing; Validation; Conceptualization; P.N.R. — Writing — review & editing; Writing — original draft; Conceptualization; Validation; Supervision

Use of Generative AI: The authors did not use generative AI tools in the conception, drafting, or revision of this manuscript.

References

1. Tande AJ, Patel R. Prosthetic joint infection. Clin Microbiol Rev. 2014;27(2):302-345 https://doi.org/10.1128/CMR.00111-13
2. Theil C, Schmidt-Braekling T, Gosheger G, Idelevich EA, Moellenbeck B, Dieckmann R. Fungal prosthetic joint infection in total hip or knee arthroplasty: a retrospective single-centre study of 26 cases. Bone Joint J. 2019;101-B(5):589-595 https://doi.org/10.1302/0301-620X.101B5.BJJ-2018-1227.R2
3. Schoof B, Jakobs O, Schmidl S, Klatte TO, Frommelt L, Gehrke T, et al. Fungal periprosthetic joint infection of the hip: a systematic review. Orthop Rev (Pavia). 2015;7(1):5748 https://doi.org/10.4081/or.2015.5748
4. Shang G, Zhao S, Yang S, Li J. The heavy burden and treatment challenges of fungal periprosthetic joint infection: a systematic review of 489 joints. BMC Musculoskelet Disord. 2024;25(1):648 https://doi.org/10.1186/s12891-024-07616-6
5. Pham CD, Iqbal N, Bolden CB, Kuykendall RJ, Harrison LH, Farley MM, et al. Role of FKS mutations in Candida glabrata: MIC values, echinocandin resistance, and multidrug resistance. Antimicrob Agents Chemother. 2014;58(8):4690-4696 https://doi.org/10.1128/AAC.03255-14
6. Belden K, Cao L, Chen J, Deng T, Fu J, Guan H, et al. Hip and Knee Section, Fungal Periprosthetic Joint Infection, Diagnosis and Treatment: Proceedings of International Consensus on Orthopedic Infections. J Arthroplasty. 2019;34(2S):S387-S391 https://doi.org/10.1016/j.arth.2018.09.023
7. Nace J, Siddiqi A, Talmo CT, Chen AF. Diagnosis and management of fungal periprosthetic joint infections. J Am Acad Orthop Surg. 2019;27(18):e804-e818 https://doi.org/10.5435/JAAOS-D-18-00331
8. Parvizi J, Tan TL, Goswami K, Higuera C, Della Valle C, Chen AF, et al. The 2018 definition of periprosthetic hip and knee infection: an evidence-based and validated criteria. J Arthroplasty. 2018;33(5):1309-1314.e2 https://doi.org/10.1016/j.arth.2018.02.078
9. Pappas PG, Kauffman CA, Andes DR, Clancy CJ, Marr KA, Ostrosky-Zeichner L, et al. Clinical practice guideline for the management of candidiasis: 2016 update by the Infectious Diseases Society of America. Clin Infect Dis. 2016;62(4):e1-e50 https://doi.org/10.1093/cid/civ933
10. Goodman SM, Springer B, Guyatt G, Abdel MP, Dasa V, George M, et al. 2017 American College of Rheumatology/American Association of Hip and Knee Surgeons guideline for the perioperative management of antirheumatic medication in patients with rheumatic diseases undergoing elective total hip or total knee arthroplasty. J Arthroplasty. 2017;32(9):2628-2638 https://doi.org/10.1016/j.arth.2017.05.001
11. Borman AM, Linton CJ, Miles SJ, Johnson EM. Molecular identification of pathogenic fungi. J Antimicrob Chemother. 2008;61 Suppl 1:i7-12 https://doi.org/10.1093/jac/dkm425
12. Higuera CA, Zmistowski B, Malcom T, Barsoum WK, Sporer SM, Mommsen P, et al. Synovial fluid cell count for diagnosis of chronic periprosthetic hip infection. J Bone Joint Surg Am. 2017;99(9):753-759 https://doi.org/10.2106/JBJS.16.00123
13. Yeganeh MH, Kheir MM, Shahi A, Parvizi J. Rheumatoid arthritis, disease modifying agents, and periprosthetic joint infection: what does a joint surgeon need to know? J Arthroplasty. 2018;33(4):1258-1264 https://doi.org/10.1016/j.arth.2017.11.031
14. Sidhu MS, Cooper G, Jenkins N, Jeys L, Parry M, Stevenson JD. Prosthetic fungal infections: poor prognosis with bacterial co-infection. Bone Joint J. 2019;101-B(5):582-588 https://doi.org/10.1302/0301-620X.101B5.BJJ-2018-1202.R1
15. Azzam K, Parvizi J, Jungkind D, Hanssen A, Springer B, Fehring T, et al. Microbiological, clinical, and surgical features of fungal prosthetic joint infections: a multi-institutional experience. J Bone Joint Surg Am. 2009;91 Suppl 6:142-149 https://doi.org/10.2106/JBJS.I.00574
16. Goss B, Lutton C, Weinrauch P, Jabur M, Gillett G, Crawford R. Elution and mechanical properties of antifungal bone cement. J Arthroplasty. 2007;22(6):902-908 https://doi.org/10.1016/j.arth.2006.09.013
17. Houdek MT, Greenwood-Quaintance KE, Morrey ME, Patel R, Hanssen AD. Elution of high dose amphotericin B deoxycholate from polymethylmethacrylate. J Arthroplasty. 2015;30(12):2308-2310 https://doi.org/10.1016/j.arth.2015.06.002

Cite this article as: Tarong P, Purwana RA, Semita SM, Fatmawati AA, Dibyosubroto HG, Raharjo PN. pan-echinocandin-resistant candida glabrata periprosthetic hip joint infection in an immunosuppressed rheumatoid host: a case report. *OSCRSJ*. 2026;1(1):e0002. https://doi.org/10.XXXXX/oscrsj.2026.0002